

## Inhibition of Apoptosis by Hyperbaric Oxygen in a Rat Focal Cerebral Ischemic Model

\*Dali Yin, †Changman Zhou, †Ikuyo Kusaka, †John W. Calvert, \*Andrew D. Parent,  
†Anil Nanda, and †John H. Zhang

Department of \*Neurosurgery, University of Mississippi Medical Center, Jackson, Mississippi; †Department of Neurosurgery, Louisiana State University Health Science Center, Shreveport, Louisiana, U.S.A.

**Summary:** The hypothesis was tested that hyperbaric oxygen therapy (HBO) reduced brain infarction by preventing apoptotic death in ischemic cortex in a rat model of focal cerebral ischemia. Male Sprague-Dawley rats were subjected to middle cerebral artery occlusion/reperfusion (MCAO/R) and subsequently were exposed to HBO (2.5 atmospheres absolute) for 2 h, at 6 h after reperfusion. Rats were killed and brain samples were collected at 24, 48, 72 h, and 7 days after reperfusion. Neurologic deficits, infarction area, and apoptotic changes were evaluated by clinical scores, 2,3,7-triphenyltetrazolium chloride staining, caspase-3 expression, DNA fragmentation assay, and terminal deoxynucleotidyl transferase-mediated 2'-deoxyuridine 5'-triphosphate-biotin nick end labeling (TUNEL)-hematoxylin and eosin (H&E) costaining. In

MCAO/R without HBO treatment animals, DNA fragmentation was observed in injured cortex at 24, 48, and 72 h but not in samples at 7 days after reperfusion. Double labeling of brain slides with NeuN and caspase-3 demonstrated neurons in the injured cortex labeled with caspase-3. TUNEL+H&E costaining revealed morphologic apoptotic changes at 24, 48, and 72 h after reperfusion. Hyperbaric oxygen therapy abolished DNA fragmentation and reduced the number of TUNEL-positive cells. Hyperbaric oxygen therapy reduced infarct area and improved neurologic scores at 7 days after reperfusion. One of the molecular mechanisms of HBO-induced brain protection is to prevent apoptosis, and this effect of HBO might preserve more brain tissues and promote neurologic functional recovery. **Key Words:** Cerebral ischemia—HBO—Apoptosis—Infarction.

Cell death, either necrosis or apoptosis, occurred in the brain tissues during the first few days after cerebral ischemia (Johnson et al., 1995; Rink et al., 1995). Necrotic cell death is characterized by cellular swelling, nuclear pyknosis with karyorrhexis, and cytoplasmic eosinophilia (Searle et al., 1982; Dure et al., 1995). Apoptosis is characterized by morphologic and biochemical features, including cell shrinkage, formation of apoptotic bodies, and extensive internucleosomal fragmentation (Johnson Jr et al., 1995, 1996). Cerebral hypoxia/ischemia produces a cascade of interconnected pathologic processes, including changes in intracellular  $\text{Ca}^{2+}$ , excitatory amino acid, oxidative stress, and inflammatory response, and leads to apoptosis in the ischemic penumbra (Okamoto et al., 1993; Johnson Jr et al., 1995; Rink et al., 1995; Leker et al., 1999). Prevention of apoptosis becomes a therapeutic strategy to preserve brain tis-

ues and promote functional recovery (Graham and Chen, 2001).

Hyperbaric oxygen therapy (HBO) is a potent mean to increase the amount of oxygen dissolved in blood plasma and thereby delivered to the ischemic brain. However, HBO is not currently used in acute stroke management, partially due to the insufficient information of its molecular mechanisms (Kawamura et al., 1990; Anderson et al., 1991; Mink and Dutka, 1995; Nighoghossian and Trouillas, 1997; Chuba et al., 1997; Roos et al., 1998; Veltkamp et al., 2000; Badr et al., 2001a). We have found previously that HBO regulates brain metabolism (Badr et al., 2001b) and reduces the expression of COX-2 (Yin et al., 2002); it affects both neuronal injury and cell survival. In one of our recent studies, we have shown in a neonatal hypoxia rat model that apoptotic bodies appeared in the injured cortex and that HBO reduced the number of apoptotic cells (Calvert et al., 2002). However, because we used electron microscopy in that study, the data were not quantified. We postulated that HBO increases the oxygen level in ischemic brain regions (Sunami et al., 2000), decreases hypoxia, and reduces brain injury by inhibition of apoptosis. We

Received September 6, 2002; final version received April 7, 2003; accepted March 10, 2003.

Address correspondence and reprint requests to Dr. John H. Zhang, Department of Neurosurgery, Louisiana State University Health Science Center, 1501 Kings Highway, Shreveport, LA 71130-3932; e-mail: johnzhang3910@yahoo.com



evaluated neurologic function, infarct areas, and apoptotic changes using specific methods including caspase-3 expression, DNA fragmentation assay, and terminal deoxynucleotidyl transferase-mediated 2'-deoxyuridine 5'-triphosphate-biotin nick end labeling (TUNEL) staining. We applied HBO in the present study 6 h after ischemia and reperfusion to test HBO as a potential additional or alternative therapy for patients with acute stroke.

## MATERIALS AND METHODS

These studies comply with the National Institute of Health's Guide for Care and Use of Laboratory Animals and are approved by the Institutional Animal Care and Use Committee at the University Mississippi Medical Center and at the Louisiana State University Health Science Center–Shreveport.

### Preparation of middle cerebral artery occlusion/reperfusion rat model

Male Sprague-Dawley rats, weighing 300 to 350 g, were subjected to middle cerebral artery occlusion (MCAO) as described by Kittaka et al. (1997) and as described previously (Badr et al., 2001b). Briefly, the rats were anesthetized with an intraperitoneal injection of ketamine (80 mg/kg) and xylazine (10 mg/kg) and were allowed to breathe spontaneously. A supplemental dose of anesthetics was added if necessary. With the aid of a microscope, the left common carotid artery was exposed, and the external carotid artery was isolated and coagulated. A 3-0 nylon suture with a blunted tip was inserted into the internal carotid artery through the external carotid artery stump and was gently advanced to occlude the middle cerebral artery. After 2 h of MCA occlusion, the suture was carefully removed to restore blood flow; the skin was sutured; and the rats were allowed to wake up. To complete the surgery, the operator applied 0.25% miconazole (Sigma, St. Louis, MO, U.S.A.) locally to the wound and allowed the rat to recover. Body temperature was maintained with a heating blanket at  $37 \pm 0.5^\circ\text{C}$  during surgery and before they awoke from surgery. A successful occlusion of the left MCA is assumed when the right

forelimb is paretic after filament introduction (Veltkamp et al., 2000).

### Hyperbaric oxygen treatment

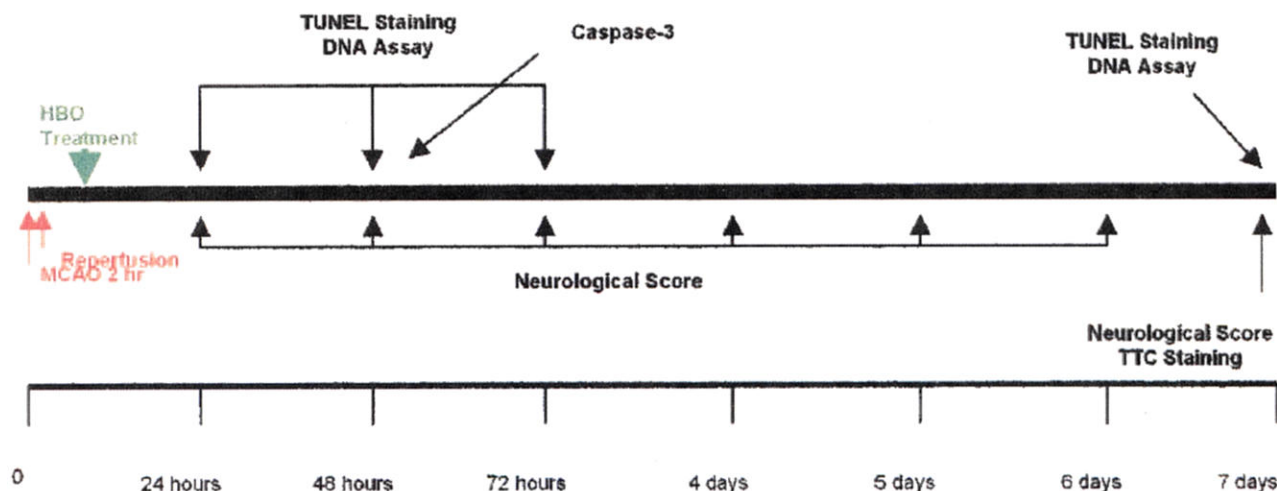
The rats were placed into an HBO chamber [2.5 atmospheres absolute (ATA)] for 2 h for one treatment as described previously (Badr et al., 2001a,b; Yin et al., 2002). The HBO treatment was performed at 6 h after reperfusion. On reaching the desired pressure, the flow of oxygen (100%) was reduced to maintain constant pressure while allowing a flow out of the chamber. This constant exchange accompanied by a tray of calcium carbonate crystals was used to reduce the accumulation of  $\text{CO}_2$  in the chamber environment. After HBO, the rats were placed back into the cage until they were killed. Body temperature was not changed markedly or significantly (within  $0.5^\circ\text{C}$ ) after HBO as shown previously (Badr et al., 2001a).

### Experimental protocol

Fifty-four rats were divided randomly into the following 3 groups: control (sham surgery), middle cerebral artery occlusion/reperfusion (MCAO/R), and MCAO/R with HBO treatment. The rats in control group ( $n = 6$ ) underwent left common carotid artery and external carotid exposure without MCA occlusion, and did not undergo HBO treatment. In MCAO/R group ( $n = 24$ ), the MCA was occluded for 2 h and reperfusion without HBO treatment. In the MCAO/R with HBO group ( $n = 24$ ), HBO was applied at 6 h after reperfusion. The experimental protocol is shown in Fig. 1. The designed reperfusion duration was 24 h, 48 h, 72 h, and 7 days, respectively. The animals were not anesthetized and breathed spontaneously during HBO treatment. All animals were observed closely from 24 h to 7 days to evaluate neurologic function. On a designated time after reperfusion, the rats were killed, their brains were quickly removed, and samples were collected for infarction ratio and apoptosis.

### Neurologic evaluation

At designated times, neurologic deficits of rats with and without HBO treatment were evaluated according to the method developed by Menzies et al. (1992) and as described previously (Badr et al., 2001a). A grade of 0 indicates no visible neurologic deficits. A grade of 1 is



**FIG. 1.** Flow chart illustrates the timing of middle cerebral artery occlusion (MCAO)/reperfusion, hyperbaric oxygen therapy (HBO) treatment, neurological score, 2,3,7-triphenyltetrazolium chloride (TTC) staining, caspase-3 expression, terminal deoxynucleotidyl transferase-mediated 2'-deoxyuridine 5'-triphosphate-biotin nick end labeling (TUNEL) staining and DNA assay.



given to an animal displaying forelimb flexion. The animal is then placed on an absorbent pad and gently pulled by the tail. If the animal shows a weakness in grip in the contralateral forelimb, it receives a grade of 2. The animal is then allowed to move about freely. If it circles to the paretic side only when pulled by the tail, a grade 3 is assigned. However, if it spontaneously circles, a grade of 4 is assigned.

#### TTC staining

2,3,7-Triphenyltetrazolium chloride (TTC) staining was performed at 7 days after reperfusion as described previously (Badr et al., 2001b; Yin et al., 2002). Coronal sections of the brain (2 mm thick) were cut and immersed in a 2% solution of TTC for 30 minutes at 37°C. The stained slices were then fixed by immersion in 10% formaldehyde solution. The infarction area and hemisphere area of each section were traced and measured using an image analysis system [SigmaScan/Image (Image Measurement Soft), Jandel Scientific Software, San Rafael, CA, U.S.A.]. The percentage of infarction (infarct ratio) was calculated by dividing the infarct volume by the total volume of the ipsilateral hemisphere.

#### DNA fragmentation assay

After the brains were removed, a 4-mm-thick coronal brain slice was cut at the level of optic chiasm, and the cortex including infarction was dissected using the corpus callosum as a ventral landmark. Analysis of DNA fragmentation was performed using methods described previously (Yin et al., 1994; Meguro et al., 2001a,b). Tissues from brain cortex including infarcted area were homogenized and centrifuged briefly and washed twice with cold PBS. The pellet was lysed in 1.0 mL of a buffer consisting of 10 mmol/L Tris-HCl, 10 mmol/L ethylenediamine tetraacetic acid (EDTA) and 0.2% Triton X-100 (pH 7.5). After 10 minutes on ice, the lysate was centrifuged (13,000g) for 10 minutes at 4°C. The RNA and fragmented DNA in the supernatant were extracted, first with phenol and then with phenol-chloroform-isoamyl alcohol (25:24:1, vol:vol). The aqueous phase was added to 300 mmol/L NaCl, and the nucleic acids were precipitated with 2 volumes of ethanol. The pellet was rinsed with 70% ethanol, air dried, and then dissolved in 20  $\mu$ L of 10 mmol/L Tris-HCl-1 mmol/L EDTA (pH 7.5). After digestion of the RNA with ribonuclease A (0.6 mg/mL at 37°C for 30 minutes), the samples were electrophoresed in a 2% agarose gel with Boyer's buffer (50 mmol/L Tris-HCl, 20 mmol/L sodium acetate, 2 mmol/L EDTA, and 18 mmol/L NaCl at pH 8.05). The DNA was visualized with ethidium bromide staining.

#### TUNEL staining

Immunohistology using the ApopTag Peroxidase In Situ Apoptosis Detection Kit (Intergen Co., Purchase, NY, U.S.A.) was employed to demonstrate apoptotic

cells in ischemic brain tissue as described previously (Ogihara et al., 2000). Five-micron-thick serial coronal sections were cut from the cortex including infarction and were affixed to a slide by heating at 37°C overnight, deparaffinized, and dehydrated. After digestion with proteinase K (20 g/mL; Sigma Chemical Co., St. Louis, MO, U.S.A.) in 0.05 mol/L PBS at room temperature for 15 minutes and extensive washes in PBS, the sections were treated with 3% hydrogen peroxide in PBS to quench endogenous peroxidase activity for removing background staining. Labeling of 3'-OH terminal DNA fragments was then performed by using the above *in situ* apoptosis detection kit according to the manufacturer's protocol. The counterstaining was performed with 1% methyl green.

Some of the slides were costained with TUNEL and hematoxylin and eosin (H&E) for the evaluation of infarction as well as apoptosis. Quantitative (number of TUNEL-positive cells) analyses were performed at the ipsilateral cortex including both ischemic core and penumbra regions. The quantification of apoptotic cells was determined by Imaging-Pro Plus. The TUNEL-positive cells displayed a brown staining within the nucleus or cytoplasm in the apoptotic cells. Because computer automatic counting might include false-positive cells, the numbers generated only show a tendency of changes of apoptosis.

#### Double fluorescent immunohistochemical staining

Frozen tissue sections were cut 8  $\mu$ m thick and were air dried for 30 minutes. Sections were incubated in 1% hydrogen peroxide (10 minutes), in 3% normal goat serum in PBS (30 minutes), and then incubated with mouse anti NeuN antibody (Chemicon Inc., 1:100) overnight at 4°C. Sections were later incubated with goat anti mouse-TXRED IgG 1:200 for 2 h. Between each step, sections were washed three times with PBS for 5 minutes each. Then the sections were treated with nonspecific binding with 3% bovine serum albumin in phosphate buffered saline with Tween-20 (PBST) and incubated with fluorescence-conjugated caspase-3 antibody (Cell Signaling Inc., 1:100), shielded from light with gentle shaking overnight at 4°C. The sections were washed twice for 10 minutes each time with PBS. The sections were mounted on coverslips, and the slides were visualized under the fluorescent microscope (Olympus). Color composite was done by Imaging-Pro Plus.

#### Data analysis

In this study, data were represented as mean  $\pm$  SD. Statistical differences between the MCAO/R group (no HBO treatment) and the other groups were compared by using the one-way analysis of variance and then Scheffé *F* test to determine whether a significant difference was found; A *P* value less than 0.05 was considered statistically significant.



## RESULTS

### Hyperbaric oxygen therapy attenuates neurologic deficits

The results of the neurologic deficit score in each group are shown in Fig. 2. In MCAO/R group, the neurologic scores were 3.2, 2.8, 2.8, and 2.6 at 24 h, 48 h, 72 h, and 7 days after reperfusion, respectively. In MCAO/R with HBO treatment group, the neurologic scores were 2.7, 2.4, and 2.3 at 24 h, 48 h, 72 h, and 1.8 at 7 days ( $P < 0.05$  vs. MCAO/R group) after reperfusion, respectively. Hyperbaric oxygen therapy enhanced neurologic recovery after MCAO/R at day 7 ( $P < 0.05$ ). No neurologic deficit was observed in the sham-operated rats.

### Hyperbaric oxygen therapy reduces cerebral infarction

The representative samples of TTC-stained brain sections from animals killed at 7 days after sham operation, MCAO/R, and MCAO/R with HBO treatment are shown in Fig. 3. The coronal sections were obtained by cutting the brain at a distance of 2, 4, 6, 8, and 10 mm from the rostral extremity of the frontal cortex. The white areas represent the infarction regions in these sections. Figure 4 shows the percentage of infarction in MCAO/R and MCAO/R with HBO treatment groups, respectively. In the MCAO/R group (untreated group), severe cerebral infarction was observed in all rats and the infarct ratio was 20.1% at 7 days. The infarct ratio was significantly decreased in rats treated with HBO after reperfusion at 7 days (12.6%,  $P < 0.05$  vs. MCAO/R).

### DNA fragmentation

To evaluate the presence of apoptosis, DNA fragmentation was assessed in the injured cortex using agarose gel electrophoresis. As shown in Fig. 5, the DNA of injured cortex exhibited nucleosomal fragmentation indicative of apoptosis at 24 h, 48 h, and 72 h after

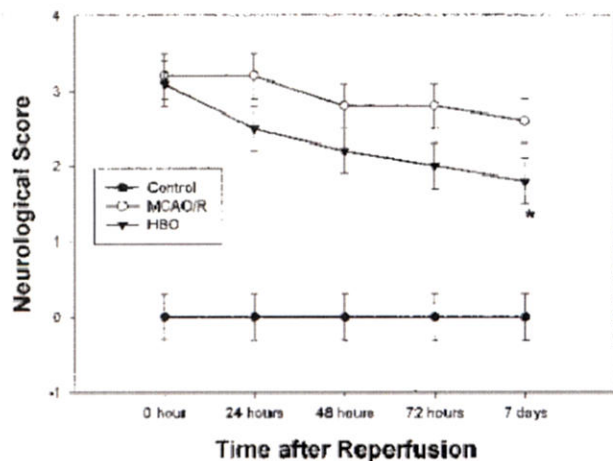


FIG. 2. Changes of neurologic scores before and after hyperbaric oxygen therapy (HBO) treatment. Grades of 0 to 4 were used. \* $P < 0.05$  versus no HBO treatment.

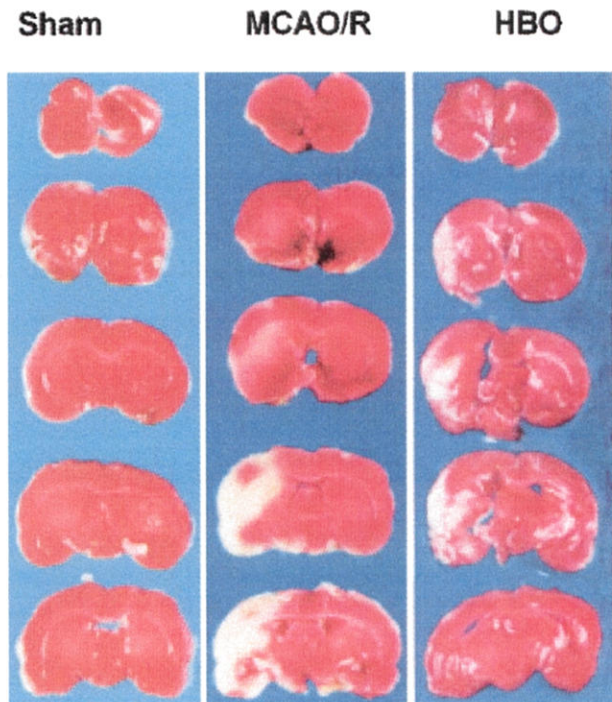


FIG. 3. 2,3,7-Triphenyltetrazolium chloride (TTC) staining. Representative sample of TTC-stained brain sections from rats killed at 7 days after ischemia. Middle cerebral artery occlusion/reperfusion (MCAO/R) animals showed severe infarctions. The white areas represent the infarct regions in these sections. In contrast, animals exposed to HBO treatment had a significant reduction in infarction.

MCAO/R. At 7 days after reperfusion, no DNA ladder was observed in the cortex. No clear DNA ladder was observed in the injured cortex of rats that received HBO, even though some smear patterns are shown indicating necrosis (Ogihara et al., 1999). No detectable DNA fragmentation was found in the sham-operated animals (not shown).

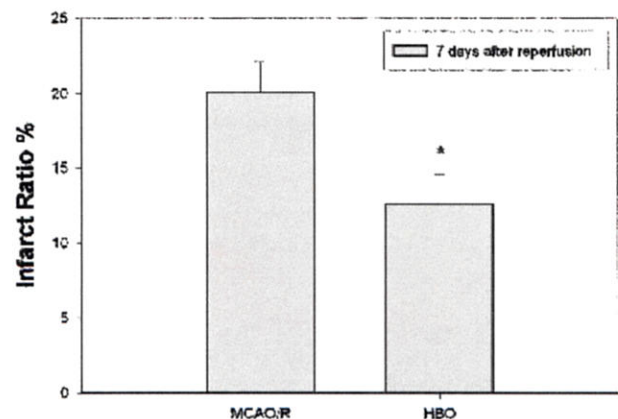
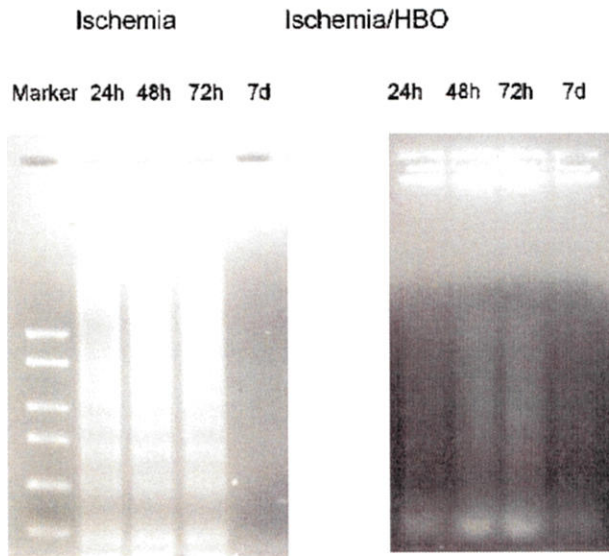


FIG. 4. Changes of infarct volume after hyperbaric oxygen therapy (HBO) treatment. The infarct ratio was calculated as the percentage of infarcted tissue per ipsilateral hemisphere. \* $P < 0.05$  versus no HBO treatment. MCAO/R, middle cerebral artery occlusion/reperfusion.





**FIG. 5.** Results of agarose gel electrophoresis. DNA fragmentation was induced at 24 h, 48 h, and 72 h, but not 7 days after ischemic brain injury. No DNA fragmentation was observed after hyperbaric oxygen therapy (HBO) treatment. The left lane shows the molecular weight marker. The same experiment was performed three times with similar results.

### Caspase expression

Figure 6 demonstrates that in contralateral cortex (no ischemia) of a MCAO rat reperfusion for 48 h, neurons were stained to NeuN (red) but not to caspase-3 (green, insert). In the injured cortex, neurons were stained to both NeuN and caspase-3. Higher magnification shows same cells stained to both NeuN and caspase-3. Color composition indicates that NeuN was stained to the nucleus and caspase-3 around NeuN in the cytosol.

### TUNEL staining analysis

Intense punctate or diffuse nuclear brown staining of the affected cells identified TUNEL-positive labeling. The TUNEL-positive cells were characterized by a round and shrunken morphology. The nuclei were round, condensed, and frequently fragmented into intensely TUNEL-positive nuclear fragments. The number of TUNEL-positive cells was counted in the ipsilateral cortex by Imaging-Pro Plus for the times 24 h, 48 h, 72 h, and 7 days after reperfusion, respectively. Because this counting by computer might have a degree of false positive, the numbers represent a tendency of apoptotic changes after reperfusion and after HBO treatment only. TUNEL-positive cells occurred mostly at 24 h, 48 h, and 72 h after reperfusion and disappeared at 7 days. Table 1 shows the number of TUNEL-positive cells, and HBO reduced significantly the number of positive cells. Control animals revealed no staining for TUNEL.

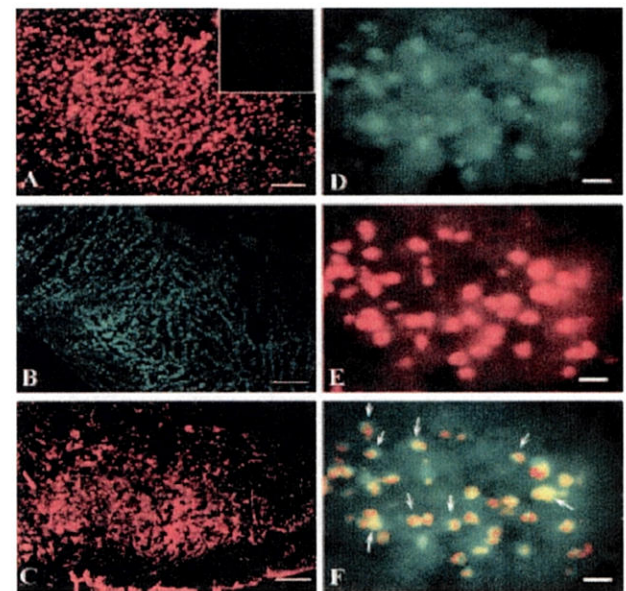
Some brain slides were costained with TUNEL and H&E to demonstrate morphologic changes as well as apoptotic changes. Figure 7 shows the infarction area and apoptotic cells in brain samples collected at 24 h after

reperfusion. Even though strong staining (brown color) is shown in most cells in the ischemic cortex, the neurons and their process kept their normal shape (Fig. 7E). At 48 h after reperfusion, the process begins to disappear and the neuronal body becomes rounded with strong TUNEL staining in the nucleus (Fig. 8E). All cells become rounded in shape and lost their processes at 72 h after reperfusion (Fig. 9E). After 7 days, scar tissues filled ischemic regions with a few cells stained H&E without process (Fig. 10E).

Hyperbaric oxygen therapy reduced infarcted areas at 24 h (Fig. 7B), 48 h (Fig. 8B), 72 h (Fig. 9B), and 7 days (Fig. 10B); it decreased TUNEL-positive cells at 24 h (Fig. 7D), 48 h (Fig. 8D), and 72 h (Fig. 9D). In the ischemic cortex in animals treated with HBO, a significant number of TUNEL-negative cells exist and stained with H&E (Figs. 7–9F). In samples collected from HBO-treated animals at 7 days, many cells with processes exist in the ischemic region (Fig. 10E).

### DISCUSSION

The major finding from our experiments is that HBO treatment reduced neuronal apoptotic death, which probably translated into protective effect against ischemic



**FIG. 6.** Fluorescent immunohistochemical staining of NeuN (red, Chemicon) and caspase-3 (green, Cell Signaling Tech) in samples collected from a middle cerebral artery occlusion animal killed at 48 h after reperfusion. (A) NeuN expression is shown in the contralateral side of the cortex (no ischemia). In the contralateral side cortex, caspase-3 staining is completely negative (the insert square area in top right corner of (A) (scale bar = 100  $\mu$ m). (B and C) Caspase-3 expression is shown in the injured cortex [as compared with the insert in (A)]. NeuN expression is shown in the same injured cortex area (scale bars = 200  $\mu$ m). (D and E) High magnification shows caspase-3 expression in neurons in the injured cortex. The same cells express NeuN (scale bars = 10  $\mu$ m). (F) Color composite shows NeuN (red) stained the nucleolus (yellow or orange) and caspase-3 (green) stained cytosol (arrows) (scale bar = 10  $\mu$ m).



TABLE 1. Percentages of TUNEL cells

Groups	TUNEL cells		Total cells		% TUNEL/total		P value Student's <i>t</i> -test
	MCA	HBO	MCA	HBO	MCA	HBO	
24 hour	3418 ± 57	1663 ± 18	15268 ± 31	10681 ± 30	22.4 ± 0.4	15.6 ± 0.2	<0.001
48 hour	3552 ± 32	2845 ± 15	10828 ± 16	15048 ± 17	32.8 ± 0.3	18.9 ± 0.1	<0.001
72 hour	3346 ± 18	2568 ± 10	10745 ± 30	11839 ± 17	31.1 ± 0.1	21.7 ± 0.1	<0.001
7 day	179 ± 21	560 ± 15	1153 ± 23	10687 ± 18	15.5 ± 1.5	5.2 ± 0.1	= 0.003

MCA, middle cerebral artery; HBO, hyperbaric oxygen therapy.

damage and decreased cerebral infarction. The effect of HBO on apoptosis was confirmed by DNA ladder and TUNEL staining in the ischemic cerebral cortex. A delayed HBO was used in the present study as an additional or alternative therapy for patients with acute stroke. The only effective treatment for acute stroke tissue plasminogen activator (tPA) can be used only in a small percentage of patients admitted into the hospital within 3 to 6 h after the onset of stroke, because the possibility of hemorrhagic transformation increases (Hamann et al., 1999; del Zoppo et al., 2000).

A rat filament occlusion and reperfusion model was used because it is a widely accepted model of reversible focal ischemia (Kittaka et al., 1997; Sharp et al., 2000). This MCAO/R rat model has been confirmed by other investigators (Singhal et al., 2002a,b) and by our previous studies (Badr et al., 2001b; Yin et al., 2002) as a reliable model for producing neurologic deficits for brain injury. The cerebral infarct and neurologic deficits after ischemia/reperfusion and the improvement after HBO are consistent with our previous publications (Badr et al., 2001a, 2001b; Yin et al., 2002).

### Apoptosis in cerebral ischemia

In focal cerebral ischemia, reduction of blood flow is generally greatest in the core or center of the area supplied by the occluded vessel. Less severe but clinically important ischemia occurs in the border regions termed the penumbra (Ginsberg and Busto, 1989; Pulsinelli, 1992; Ginsberg and Pulsinelli, 1994; Pulsinelli et al., 1997). Because cerebral energy metabolism is almost entirely aerobic and the brain has only minor reserves of energy-rich compounds, bioenergetic failure occurs rapidly in the severely hypoperfused ischemic core (Katsura et al., 1994; Siesjö et al., 1995). In contrast, cell survival or death in the potentially salvageable penumbra is not only a function of residual blood flow but also the result of various cellular and molecular events triggered by ischemic stress (Hossmann, 1994). In the absence of reperfusion, the core undergoes pannecrosis, and the penumbra sustains varying degrees of injury ranging from nonselective neuronal death to pannecrosis (Neumar, 2000).

Apoptosis is an active biologic process of eliminating unwanted cells involved in the regulation of cell number under physiologic and pathologic conditions (Savitz and

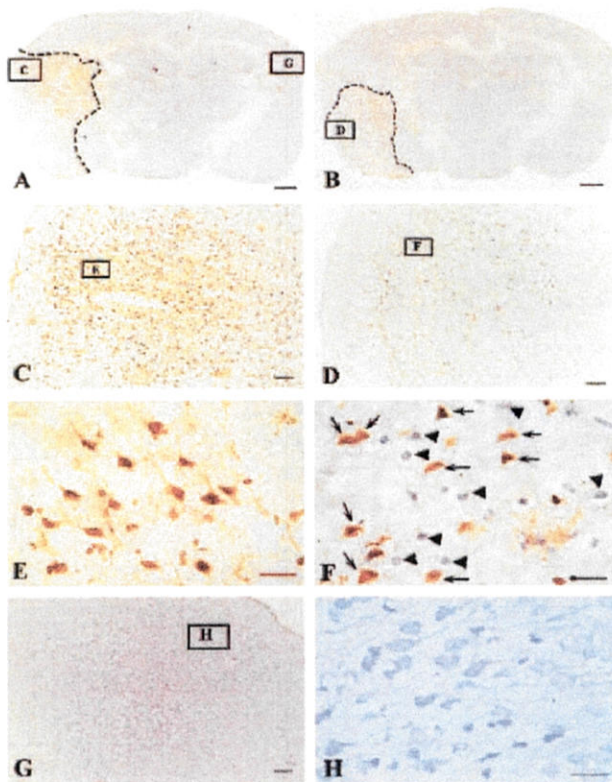
Rosenbaum, 1998). However, apoptosis plays an important role in the pathologic factors of delayed neuronal damage, especially in the penumbra after cerebral ischemia (Rink et al., 1995; Nicotera et al., 1997; Jiang et al., 2002). It has been shown previously that apoptosis occurs from 18 h to 3 or 4 days after ischemia (Ferrand-Drake and Wieloch, 1999; Ferrand-Drake, 2001; Culmsee et al., 2001). In the present study, using the MCAO/R rat model, we have found apoptotic changes in the injured cortex between 24 and 72 h after reperfusion. Caspase 3 expression, DNA fragmentation assay, and TUNEL staining support this observation. Apoptotic changes disappeared in samples 7 days after reperfusion in this model DNA ladder and TUNEL-positive cells were all almost eliminated. Our observation is consistent with a previous report that there was no evidence of apoptosis at 7 to 28 days after focal cerebral ischemia (Sugawara et al., 2000). For this reason, we did not conduct experiments beyond 7 days after reperfusion.

### Effect of hyperbaric oxygen therapy on apoptosis

The rationale of using HBO in cerebral ischemia is to increase the oxygen delivery to the ischemic tissues (penumbra) and to prolong the functional activity of these tissues (Mink and Dutka, 1995; Nighoghossian and Trouillas, 1997; Chuba et al., 1997). In our previous studies, we have found that HBO reduces infarct volume and improves neurologic recovery in MCAO/R rats (Badr et al., 2001a). hyperbaric oxygen therapy modulates brain metabolites (Badr et al., 2001b) and reduces COX-2 expression in the penumbra regions (Yin et al., 2002). Our hypothesis generated from these previous studies is that HBO increases oxygen levels in the ischemic brain regions (Sunami et al., 2000), decreases hypoxia, and reduces cerebral infarct by reducing apoptosis in the ischemic regions. The experimental results from the present study supported this hypothesis that MCAO/R produces apoptosis and HBO reduced apoptotic changes. Abolition of DNA ladders and TUNEL-positive cells by HBO confirmed the action of HBO on apoptosis. This antiapoptosis effect may be one of the important molecular mechanisms of HBO-induced brain protection and may promote neurologic improvement.

The mechanism responsible for HBO-induced anti-apoptotic effect is not clear and beyond the scope of the

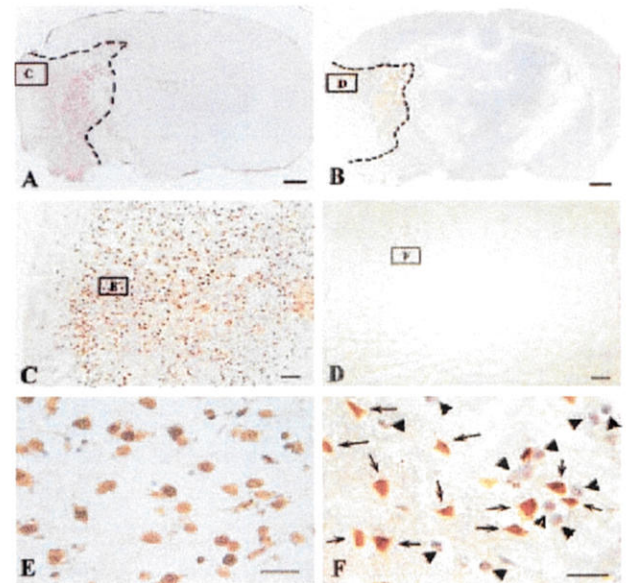




**FIG. 7.** The histologic photomicrographs of brain coronal sections in animals killed at 24 h after middle cerebral artery occlusion/reperfusion (MCAO/R) with or without hyperbaric oxygen therapy (HBO). The slides were costained with terminal deoxynucleotidyl transferase-mediated 2'-deoxyuridine 5'-triphosphate-biotin nick end labeling (TUNEL) and hematoxylin and eosin (H&E). (A, C, E) The infarction area [dashed line in (A)] and TUNEL-positive cells in the cortex at different magnifications in an animal after MCAO/R (inset boxes with letters C and E indicate the regions selected and enlarged at higher magnifications). (B, D, F) The infarcted areas (dashed line in (B)) and TUNEL cells at different magnifications in the cortex in an animal treated with HBO after MCAO/R (inset boxes with letters D and F indicate the regions selected and enlarged at higher magnifications). HBO reduced infarcted area (dash lined area in B is smaller than dash lined area in A) and decreased the density of TUNEL cells (less positive cells in area D than in area C). After MCAO/R without HBO treatment, in (E), most neurons and their processes are in relatively normal shape even though the nuclei are TUNEL stained strongly. After HBO treatment, in (F), about half of the neuronal cells are TUNEL stained (brown, arrows) and the other half of cells stained with hematoxylin and eosin (H&E) (purple, arrowheads) without TUNEL. (G and H) The contralateral side (no ischemia) of the brain from the same animal exposed to MCAO/R without HBO treatment. No TUNEL-positive cells were observed and healthy neuronal cells stained with H&E (purple color). Scale bars: A and B = 1 mm; C, D and G = 200 μm; E, F, and H = 20 μm.

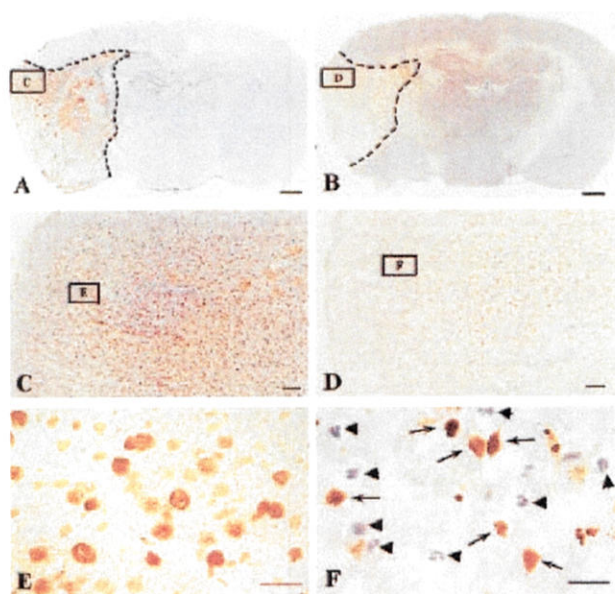
present study. Hyperbaric oxygen therapy increases tissue oxygen delivery, especially to areas of diminished flow, enhances neuronal viability, reduces brain edema, improves the integrity of the blood-brain barrier, and regulates postischemia metabolism (Nighoghossian and Trouillas, 1997; Veltkamp et al., 2000). Hyperbaric oxygen therapy improves brain metabolites (Badr et al.,

2001b), reduces the elevated expression of COX-2 (Yin et al., 2002), inhibits the function of neutrophil  $\beta$ -2-integrin, a molecule involved in leukocyte adhesion and reperfusion injury, and reduces neutrophil sequestration (Atochin et al., 2000). Buras (Buras, 2000; Buras et al., 2000) suggested that HBO might affect many of the components involved in ischemic-reperfusion injury (in peripheral tissues) including polymorphonuclear leukocyte function, endothelial cellular adhesion molecules (CAM) expression, nitric oxide production, nitric oxide synthase expression, cellular energetics, lipid peroxidation, and microvascular blood flow. All of these mechanisms may contribute to the reduction of apoptosis after HBO in the ischemic penumbra. The possible apoptotic pathways such as caspases, bcl-2 family, and poly (ADP-ribose) polymerase (PARP) involved in the effect of HBO remain to be determined. We postulate that HBO



**FIG. 8.** The histologic photomicrographs of brain coronal sections in animals killed at 48 h after middle cerebral artery occlusion/reperfusion (MCAO/R) with or without hyperbaric oxygen therapy (HBO). The slides were costained by terminal deoxynucleotidyl transferase-mediated 2'-deoxyuridine 5'-triphosphate-biotin nick end labeling (TUNEL) and hematoxylin and eosin (H&E). (A, C, E) The infarction area (dashed line in (A)) and TUNEL-positive cells in the cortex at different magnifications in an animal after MCAO/R (inset boxes with letters C and E indicate the regions selected and enlarged at higher magnifications). (B, D, F) The infarcted areas [dashed line in (B)] and TUNEL cells at different magnifications in the cortex in an animal treated with HBO after MCAO/R (inset boxes with letters D and F indicate the regions selected and enlarged at higher magnifications). HBO reduced infarcted area (dash lined area in B is smaller than dash lined area in A) and decreased the density of TUNEL cells (fewer positive cells in area D than in area C). After MCAO/R without HBO treatment, in (E), many neurons and their processes lost their normal shape and the nucleuses are TUNEL stained strongly. After HBO treatment, in (F), many neuronal cells are stained TUNEL negative and stained with H&E (purple, arrowheads) in the presence of some TUNEL-positive cells (brown, arrows). Scale bars: A and B = 1 mm; C, D, G = 200 μm; E, F, H = 20 μm.





**FIG. 9.** The histologic photomicrographs of brain coronal sections in animals killed at 72 h after middle cerebral artery occlusion/reperfusion (MCAO/R) with or without hyperbaric oxygen therapy (HBO). The slides were costained by terminal deoxynucleotidyl transferase-mediated 2'-deoxyuridine 5'-triphosphate-biotin nick end labeling (TUNEL) and hematoxylin and eosin (H&E). (A, C, E) The infarction area (dashed line in A) and TUNEL-positive cells in the cortex at different magnifications in an animal after MCAO/R (inset boxes with letters C and E indicate the regions selected and enlarged at higher magnifications). (B, D, F) The infarcted areas (dashed line in B) and TUNEL cells at different magnifications in the cortex in an animal treated with HBO after MCAO/R (inset boxes with letters D and F indicate the regions selected and enlarged at higher magnifications). HBO reduced infarcted area (dash lined area in B is smaller than dash lined area in A) and decreased the density of TUNEL cells (fewer positive cells in area D than in area C). After MCAO/R without HBO treatment, in (E), most neurons lost their normal shape, became rounded, and the nuclei are TUNEL stained. After HBO treatment, in (F), again many neuronal cells are stained TUNEL negative and stained with H&E (purple, arrowheads) in the presence of some TUNEL-positive cells (brown, arrows). Scale bars: A and B = 1 mm; C, D, G = 200  $\mu$ m; E, F, H = 20  $\mu$ m.

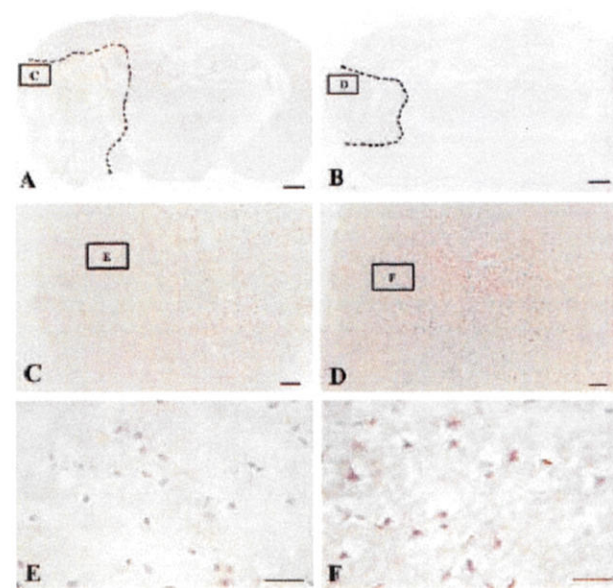
interrupts apoptotic signals or biochemical cascades and reduces cerebral infarct after ischemia and reperfusion. If HBO reduces apoptosis, especially when applied at 6 h after reperfusion (8 h after initial ischemia), HBO might be used as alternative or additional therapy for patients who have had acute stroke, because no effective treatment is available and the current Food and Drug Administration-approved therapy tPA needs to be administered within 3 to 6 h after stroke.

#### Possible side effect of hyperbaric oxygen therapy

The side effect of pressured oxygen therapy has been noted especially for high pressure (>3 ATA) and long duration. It has been shown that HBO (4.96 ATA for 1 h) administered to rats can cause CNS toxicity (Blenkarn et al., 1969). A previous study has shown that exposing rats to 4 ATA of oxygen for 90 minutes was associated with

an increased level of lipid peroxidation product, and altered enzymatic antioxidation (glutathione peroxidase) in the brain (Pablos et al., 1997). High level of HBO reduced cerebral blood flow, possibly by reducing NOS (Demchenko et al., 2000). Chavko et al. (2001) stated that 100% O<sub>2</sub> at 5 ATA induced seizures. Long-term use of HBO results in adverse effects because of the onset of oxygen toxicity as manifested by the induction of lipid peroxidation and seizures (Nighoghossian and Trouillas, 1997).

At lower pressure, Mink and Dutka (1995) found that HBO (2.8 ATA for 75 minutes) was not associated with an increase of lipid peroxidation or with a reduction of neurophysiologic recovery, despite increased amounts of oxygen free radicals in the brain in a global cerebral



**FIG. 10.** The histologic photomicrographs of brain coronal sections in animals killed at 7 days after middle cerebral artery occlusion/reperfusion (MCAO/R) with or without hyperbaric oxygen therapy (HBO). The slides were costained by terminal deoxynucleotidyl transferase-mediated 2'-deoxyuridine 5'-triphosphate-biotin nick end labeling (TUNEL) and hematoxylin and eosin (H&E). (A, C, E) The infarction area (dashed line in A) and the fragments of some dead cells and scar tissue in the cortex at different magnifications in an animal after MCAO/R (inset boxes with letters C and E indicate the regions selected and enlarged at higher magnifications). TUNEL-positive cells observed in brain slides at 24, 48, and 72 h have all disappeared after 7 days. (B, D, F) The infarcted areas (dashed line in B) and again the fragments of some dead cells and scar tissue at different magnifications in the cortex in an animal treated with HBO after MCAO/R (inset boxes with letters D and F indicate the regions selected and enlarged at higher magnifications). HBO reduced infarcted area (dash lined area in B is smaller than dash lined area in A) and preserved some normal tissue or neuronal cells (F). After MCAO/R without HBO treatment, in (E), few rounded cells stained by H&E exist. After HBO treatment, in (F), some neuronal cells with process exist in the injured area. Scale bars: A and B = 1 mm; C, D, G = 200  $\mu$ m; E, F, H = 20  $\mu$ m. (The infarcted area in this particular animal seems larger than other MCAO/R animals, which does not necessarily mean infarction grown after 7 days).



ischemic model in rabbits. The authors suggested that HBO applied immediately after global cerebral ischemia does not promote early brain injury. This report is supported by other studies using similar models (Sunami et al., 2000). Thus, the Committee of the Undersea and Hyperbaric Medical Society recommends that a treatment pressure only from 2.4 to 3.0 ATA should be used at the lowest effective pressure to avoid O<sub>2</sub> convulsions (Chavko et al., 2001). Our treatment protocol of using 2.5 ATA is similar to that of Mink and Dutka (1995), and our protocol may not enhance lipid peroxidation in the injured brain tissues.

## REFERENCES

- Anderson DC, Bottini AG, Jagiella WM, Westphal B, Ford S, Rockswold GL, Loewenson RB (1991) A pilot study of hyperbaric oxygen in the treatment of human stroke. *Stroke* 22:1137-1142
- Atochin DN, Fisher D, Demchenko IT, Thom SR (2000) Neutrophil sequestration and the effect of hyperbaric oxygen in a rat model of temporary middle cerebral artery occlusion. *Undersea Hyperb Med* 27:185-190
- Badr AE, Yin W, Mychaskiw G, Zhang JH (2001a) Dual effect of HBO on cerebral infarction in MCAO rats. *Am J Physiol Regul Integr Comp Physiol* 280:R766-R770
- Badr AE, Yin W, Mychaskiw G, Zhang JH (2001b) Effect of hyperbaric oxygen on striatal metabolites: a microdialysis study in awake freely moving rats after MCA occlusion. *Brain Res* 916:85-90
- Blenkarn GD, Schanberg SM, Saltzman HA (1969) Cerebral amines and acute hyperbaric oxygen toxicity. *J Pharmacol Exp Ther* 166:346-353
- Buras J (2000) Basic mechanisms of hyperbaric oxygen in the treatment of ischemia-reperfusion injury. *Int Anesthesiol Clin* 38:91-109
- Buras JA, Stahl GL, Svoboda KK, Reenstra WR (2000) Hyperbaric oxygen downregulates ICAM-1 expression induced by hypoxia and hypoglycemia: the role of NOS. *Am J Physiol Cell Physiol* 278:C292-C302
- Calvert J, Yin W, Patel M, Badr A, Mychaskiw G, Parent AD, Zhang JH (2002) Hyperbaric oxygenation prevented brain injury induced by hypoxia-ischemia in a neonatal rat model. *Brain Res* 951:1
- Chavko M, Xing G, Keyser DO (2001) Increased sensitivity to seizures in repeated exposures to hyperbaric oxygen: role of NOS activation. *Brain Res* 900:227-233
- Chuba PJ, Aronin P, Bhambhani K, Eichenhorn M, Zamarano L, Cianci P, Muhlbauer M, Porter AT, Fontanesi J (1997) Hyperbaric oxygen therapy for radiation-induced brain injury in children. *Cancer* 80:2005-2012
- Culmsee C, Zhu Y, Kriegstein J, Mattson MP (2001) Evidence for the involvement of Par-4 in ischemic neuron cell death. *J Cereb Blood Flow Metab* 21:334-343
- del Zoppo G, Ginis I, Hallenbeck JM, Iadecola C, Wang X, Feuerstein GZ (2000) Inflammation and stroke: putative role for cytokines, adhesion molecules and iNOS in brain response to ischemia. *Brain Pathol* 10:95-112
- Demchenko IT, Boso AE, Bennett PB, Whorton AR, Piantadosi CA (2000) Hyperbaric oxygen reduces cerebral blood flow by inactivating nitric oxide. *Nitric Oxide* 4:597-608
- Dure LS, Wiess S, Standaert DG, Rudolf G, Testa CM, Young AB (1995) DNA fragmentation and immediate early gene expression in rat striatum following quinolinic acid administration. *Exp Neurol* 133:207-214
- Ferrand-Drake M (2001) Cell death in the choroid plexus following transient forebrain global ischemia in the rat. *Microsc Res Tech* 52:130-136
- Ferrand-Drake M, Wieloch T (1999) The time-course of DNA fragmentation in the choroid plexus and the CA1 region following transient global ischemia in the rat brain. The effect of intra-ischemic hypothermia. *Neuroscience* 93:537-549
- Ginsberg MD, Busto R (1989) Rodent models of cerebral ischemia. *Stroke* 20:1627-1642
- Ginsberg MD, Pulsinelli WA (1994) The ischemic penumbra, injury thresholds, and the therapeutic window for acute stroke. *Ann Neurol* 36:553-554
- Graham SH, Chen J (2001) Programmed cell death in cerebral ischemia. *J Cereb Blood Flow Metab* 21:99-109
- Hamann GF, del Zoppo GJ, von Kummer R (1999) Hemorrhagic transformation of cerebral infarction—possible mechanisms. *Thromb Haemost* 82(suppl 1):92-94
- Hossmann KA (1994) Viability thresholds and the penumbra of focal ischemia. *Ann Neurol* 36:557-565
- Jiang Y, Wu J, Keep RF, Hua Y, Hoff JT, Xi G (2002) Hypoxia-inducible factor-1 $\alpha$  accumulation in the brain after experimental intracerebral hemorrhage. *J Cereb Blood Flow Metab* 22:689-696
- Johnson EM Jr, Greenlund LJ, Akins PT, Hsu CY (1995) Neuronal apoptosis: current understanding of molecular mechanisms and potential role in ischemic brain injury. *J Neurotrauma* 12:843-852
- Johnson S, Young-Chan CS, Laping NJ, Finch CE (1996) Perforant path transection induces complement C9 deposition in hippocampus. *Exp Neurol* 138:198-205
- Katsura K, Kristian T, Siesjö BK (1994) Energy metabolism, ion homeostasis, and cell damage in the brain. *Biochem Soc Trans* 22:991-996
- Kawamura S, Yasui N, Shirasawa M, Fukasawa H (1990) Therapeutic effects of hyperbaric oxygenation on acute focal cerebral ischemia in rats. *Surg Neurol* 34:101-106
- Kittaka M, Giannotta SL, Zelman V, Correale JD, DeGiorgio CM, Weiss MH, Zlokovic BV (1997) Attenuation of brain injury and reduction of neuron-specific enolase by nicardipine in systemic circulation following focal ischemia and reperfusion in a rat model. *J Neurosurg* 87:731-737
- Leker RR, Shohami E, Abramsky O, Ovadia H (1999) Dexanabinol; a novel neuroprotective drug in experimental focal cerebral ischemia. *J Neurol Sci* 162:114-119
- Meguro T, Chen B, Lancon J, Zhang JH (2001a) Oxyhemoglobin induces caspase-mediated cell death in cerebral endothelial cells. *J Neurochem* 77:1128-1135
- Meguro T, Chen B, Parent AD, Zhang JH (2001b) Caspase inhibitors attenuate oxyhemoglobin-induced apoptosis in endothelial cells. *Stroke* 32:561-566
- Menzies SA, Hoff JT, Betz AL (1992) Middle cerebral artery occlusion in rats: a neurological and pathological evaluation of a reproducible model. *Neurosurgery* 31:100-106
- Mink RB, Dutka AJ (1995) Hyperbaric oxygen after global cerebral ischemia in rabbits does not promote brain lipid peroxidation. *Crit Care Med* 23:1398-1404
- Neumar RW (2000) Molecular mechanisms of ischemic neuronal injury. *Ann Emerg Med* 36:483-506
- Nicotera P, Ankarcrona M, Bonfoco E, Orrenius S, Lipton SA (1997) Neuronal necrosis and apoptosis: two distinct events induced by exposure to glutamate or oxidative stress. *Adv Neurol* 72:95-101
- Nighoghossian N, Trouillas P (1997) Hyperbaric oxygen in the treatment of acute ischemic stroke: an unsettled issue. *J Neurol Sci* 150:27-31
- Ogihara K, Zubkov AY, Bernanke DH, Lewis AI, Parent AD, Zhang JH (1999) Oxyhemoglobin-induced apoptosis in cultured endothelial cells. *J Neurosurg* 91:459-465
- Ogihara K, Zubkov AY, Parent AD, Zhang JH (2000) Oxyhemoglobin produces necrosis in cultured smooth muscle cells. *Acta Neurochir Suppl* 76:507-510
- Okamoto M, Matsumoto M, Ohtsuki T, Taguchi A, Mikoshiba K, Yanagihara T, Kamada T (1993) Internucleosomal DNA cleavage involved in ischemia-induced neuronal death. *Biochem Biophys Res Commun* 196:1356-1362
- Pablos MI, Reiter RJ, Chuang JJ, Ortiz GG, Guerrero JM, Sewerynek E, Agapito MT, Melchiorri D, Lawrence R, Deneke SM (1997) Acutely administered melatonin reduces oxidative damage in lung and brain induced by hyperbaric oxygen. *J Appl Physiol* 83:354-358



- Pulsinelli W (1992) Pathophysiology of acute ischaemic stroke. *Lancet* 339:533–536
- Pulsinelli WA, Jacewicz M, Levy DE, Petito CK, Plum F (1997) Ischemic brain injury and the therapeutic window. *Ann NY Acad Sci* 835:187–193
- Rink A, Fung KM, Trojanowski JQ, Lee VM, Neugebauer E, McIntosh TK (1995) Evidence of apoptotic cell death after experimental traumatic brain injury in the rat. *Am J Pathol* 147:1575–1583
- Roos JA, Jackson-Friedman C, Lyden P (1998) Effects of hyperbaric oxygen on neurologic outcome for cerebral ischemia in rats. *Acad Emerg Med* 5:18–24
- Savitz SI, Rosenbaum DM (1998) Apoptosis in neurological disease. *Neurosurgery* 42:555–572
- Searle J, Kerr JF, Bishop CJ (1982) Necrosis and apoptosis: distinct modes of cell death with fundamentally different significance. *Pathol Annu* 17(pt 2):229–259
- Sharp FR, Lu A, Tang Y, Millhorn DE (2000) Multiple molecular penumbras after focal cerebral ischemia. *J Cereb Blood Flow Metab* 20:1011–1032
- Siesjo BK, Katsura K, Kristian T (1995) The biochemical basis of cerebral ischemic damage. *J Neurosurg Anesthesiol* 7:47–52
- Singhal AB, Dijkhuizen RM, Rosen BR, Lo EH (2002a) Normobaric hyperoxia reduces MRI diffusion abnormalities and infarct size in experimental stroke. *Neurology* 58:945–952
- Singhal AB, Wang X, Sumii T, Mori T, Lo EH (2002b) Effects of normobaric hyperoxia in a rat model of focal cerebral ischemia-reperfusion. *J Cereb Blood Flow Metab* 22:861–868
- Sugawara T, Kawase M, Lewen A, Noshita N, Gasche Y, Fujimura M, Chan PH (2000) Effect of hypotension severity on hippocampal CA1 neurons in a rat global ischemia model. *Brain Res* 877:281–287
- Sunami K, Takeda Y, Hashimoto M, Hirakawa M (2000) Hyperbaric oxygen reduces infarct volume in rats by increasing oxygen supply to the ischemic periphery. *Crit Care Med* 28:2831–2836
- Veltkamp R, Warner DS, Domoki F, Brinkhous AD, Toole JF, Busija DW (2000) Hyperbaric oxygen decreases infarct size and behavioral deficit after transient focal cerebral ischemia in rats. *Brain Res* 853:68–73
- Yin D, Kondo S, Takeuchi J, Morimura T (1994) Induction of apoptosis in murine ACTH-secreting pituitary adenoma cells by bromocriptine. *FEBS Lett* 339:73–75
- Yin W, Badr AE, Mychaskiw G, Zhang JH (2002) Down regulation of COX-2 is involved in hyperbaric oxygen treatment in a rat transient focal cerebral ischemia model. *Brain Res* 926:165–171