

PEDIATRICS®

Quantification of Neurocognitive Changes Before, During, and After Hyperbaric Oxygen Therapy in a Case of Fetal Alcohol Syndrome

Kenneth P. Stoller

Pediatrics 2005;116;586-591; originally published online Sep 15, 2005;

DOI: 10.1542/peds.2004-2851

This information is current as of October 1, 2005

The online version of this article, along with updated information and services, is located on the World Wide Web at:

<http://www.pediatrics.org/cgi/content/full/116/4/e586>

PEDIATRICS is the official journal of the American Academy of Pediatrics. A monthly publication, it has been published continuously since 1948. PEDIATRICS is owned, published, and trademarked by the American Academy of Pediatrics, 141 Northwest Point Boulevard, Elk Grove Village, Illinois, 60007. Copyright © 2005 by the American Academy of Pediatrics. All rights reserved. Print ISSN: 0031-4005. Online ISSN: 1098-4275.

American Academy of Pediatrics

DEDICATED TO THE HEALTH OF ALL CHILDREN™



Quantification of Neurocognitive Changes Before, During, and After Hyperbaric Oxygen Therapy in a Case of Fetal Alcohol Syndrome

Kenneth P. Stoller, MD

ABSTRACT. Fetal alcohol syndrome (FAS) is the most common nonhereditary cause of mental retardation, with deficits in general intellectual functioning, learning, memory, attention, and problem-solving. Presented here is the first case in which measured neurocognitive abilities were determined before, during, and after hyperbaric oxygen therapy in a case of FAS involving a teenage male patient. Memory, reaction time, and visual motor speed assessments were compared. After 40 hyperbaric treatments with 100% oxygen at 1.5 atmospheres absolute, the patient's performance in 6 of 6 categories of the computer-administered test battery improved. Word composite (verbal) scores improved from 55% to 73%, memory composite (visual) scores improved from 38% to 55%, reaction time composites improved from 1.03 to 0.53 seconds, impulse control composite scores improved from 8 to 5, and visual motor speed scores improved from 18.6 to 19.03. The patient's subjective symptoms diminished 94%. Six months after these treatments, the patient's verbal memory was maintained at 73% without any other interventions; impulsivity continued to improve, whereas other indices did not. Thirty-three additional treatments continued to improve test performance, with verbal memory at 95%, visual memory at 57%, and a 100% reduction of subjective symptoms. This patient, with 15-year-matured FAS, benefited from a short course of low-pressure hyperbaric oxygen therapy, sustained durable cognitive improvements, and continued to exhibit improvement with another short course of treatments. *Pediatrics* 2005;116:e586–e591. URL: www.pediatrics.org/cgi/doi/10.1542/peds.2004-2851; *hyperbaric oxygen therapy, fetal alcohol syndrome*.

ABBREVIATIONS. FAS, fetal alcohol syndrome; ATA, atmospheres absolute; HBOT, hyperbaric oxygen therapy; ARND, alcohol-related neurodevelopmental disorders; DCS, decompression sickness; SPECT, single-photon emission computed tomographic.

Fetal alcohol syndrome (FAS) and alcohol-related neurodevelopmental disorders (ARND) are the leading causes of nonhereditary mental retardation. FAS is caused by maternal consumption of alcohol during pregnancy, with growth deficiencies and a characteristic set of minor facial traits that

tend to become more transparent as the child matures. In addition to deficits in general intellectual functioning, individuals with FAS/ARND often demonstrate difficulties with learning, memory, attention, and problem-solving skills, as well as mental and social impairments. Children with ARND do not have the characteristic facial defects and growth deficiencies. The prevalence of FAS in the general population of the United States is thought to be between 0.5 and 2 cases per 1000 births, and the prevalence of FAS and alcohol-related birth defects combined is at least 10 cases per 1000 births, or 1% of all births.¹ Fetal alcohol spectrum disorders is now the accepted general term describing the range of effects that can occur among individuals whose mothers drank alcohol during pregnancy. Other than supportive services, there is no treatment; according to the Centers for Disease Control and Prevention, FAS is considered irreversible and incurable.

It has been a decade since Harch et al² first used hyperbaric oxygen therapy (HBOT) for a child with a neurodevelopmental disorder in North America, after making the observation that patients with neurologic conditions who were treated with standard HBOT for chronic wound problems experienced improvement in their neurologic problems. Several years earlier, Neubauer et al^{3–5} reported several cases of single-photon emission computed tomographic (SPECT) brain imaging before and after HBOT for stroke, near drowning, and natural gas poisoning, with recovery of neurologic function. Subsequently, Harch et al^{2,6,7} performed the same sequence of SPECT scans/HBOT/SPECT scans for commercial divers with brain decompression sickness (DCS) and obtained results similar to those of Neubauer et al^{3–5} for patients with acute, subacute, or chronic carbon monoxide poisoning, patients with acute, subacute, or chronic brain DCS, and patients with chronic ischemic, hypoxic, traumatic, and/or hypoxic brain injuries.

Commercial divers with DCS of the brain or spinal cord were flown in comatose and/or paralyzed condition from the oil and gas fields of the Gulf of Mexico. These injured divers showed neurologic improvement far exceeding published reports and current expectations. The notable improvement was attributable to a protocol that treated beyond the medical standard of a few HBOT treatments. Some patients required as many as 100 treatments before reaching a clinical plateau. Minutes to hours after the onset of DCS, tissue damage continues to develop

From the Department of Pediatrics, University of New Mexico School of Medicine, Albuquerque, New Mexico.

Accepted for publication Apr 14, 2005.

doi:10.1542/peds.2004-2851

No conflict of interest declared.

Address correspondence to Kenneth P. Stoller, MD, 404 Brunn School Rd #D, Santa Fe, NM 87505. E-mail: hbotnm@netzero.net

PEDIATRICS (ISSN 0031 4005). Copyright © 2005 by the American Academy of Pediatrics.

because of persistent occlusion of blood vessels by bubbles or secondary damage to blood vessels caused by passage of bubbles. This situation is virtually identical to the pathologic processes that occur in the brains of people during and after a stroke. Although not widely known or used, HBOT is now considered an important stroke treatment strategy and proved successful in several animal and human stroke studies.⁸ The journal *Stroke* published a double-blind study showing that stroke patients who had received HBOT had less disability and better neurologic function 1 year later than those who did not receive HBOT.⁹

Treatment of acute focal cerebral ischemia with HBOT has been reported for animals and humans. In general, the results of research in animals have suggested a promising role for HBOT. Hundreds of cases of human ischemic stroke treated with HBOT have been reported. In approximately one half of the cases, improvement in status was claimed on clinical or electroencephalographic grounds.¹⁰

It seems that HBOT may play a role in the repair or reconstruction of injured lower motor neurons as well.¹¹ On the basis of the available literature, it has been suggested that HBOT may provide an effective strategy for the prevention and treatment of numerous neurologic handicaps that plague many children.¹² The senior clinicians involved in the largest randomized trial of HBOT for children with cerebral palsy,^{13,14} as well as the McGill pilot study,¹⁵ have been unequivocal regarding the benefits of HBOT for children with brain injuries.¹⁶

I adapted successfully¹⁷ a computerized neuropsychologic test battery, which was developed originally to evaluate sports concussions at the Center for Sports Medicine Sports Concussion Program of the University of Pittsburgh Medical Center,^{18,19} to evaluate victims of carbon monoxide poisoning before and after HBOT. The software evaluates and documents multiple aspects of neurocognitive functioning, including memory, brain processing speed, reaction time, and postconcussive symptoms. Furthermore, unlike standard neurocognitive testing modalities, ImPACT (Immediate Postconcussion Assessment and Cognitive Testing) has shown itself to be a reliable evaluation tool with virtually no practice effect influence on score stability.²⁰ This computerized evaluation was administered in this first documented case of HBOT for a child with FAS.

CASE REPORT

The child was found abandoned in a train station in Rustov, Russia, as a toddler and subsequently was adopted and brought to

the United States. When the patient entered school, numerous problems arose that led eventually to the diagnosis of FAS (category II, because the patient was without confirmed maternal alcohol exposure). Although the patient's exact age was not known, his legal birth date made him 15 years of age at the time of the evaluation, in which he still exhibited several key features of FAS, including classic facial anomalies and neurodevelopmental abnormalities of the central nervous system. Furthermore, it is of interest that, because of his neurocognitive state, the patient was found incompetent to stand trial for an alleged offense in the court system in New Mexico.

The patient was given the aforementioned, computer-administered, test battery, which consists of 7 individual test modules that measure aspects of cognitive functioning including attention, memory, reaction time, and processing speed (Table 1). He took a baseline test, a test midway through his HBOT, and a retest as he completed his initial block of HBOT at treatment 40. The patient was retested 6 months after HBOT and again after completing another 33 treatments.

On the basis of normative data for his age, the patient's baseline scores placed him in the impaired range (Figs 1–5; Table 2). The patient was treated with low-pressure HBOT 5 days per week, for 60 minutes at depth for each treatment (100% oxygen at 1.5 atmospheres absolute [ATA], which is equivalent to the pressure at 17 feet of seawater), in a multiplace chamber with a hood to administer the oxygen. After his 20th treatment, he was retested and demonstrated a precipitous decrease in reaction time and the beginnings of improvement in memory. As is often the case when reaction time improves, impulsivity scores increased initially. By the end of treatment, 5 of 5 composite scores of neurocognitive function showed improvement, although the patient's verbal and visual memory scores still placed him in the borderline impaired range. Impulsivity control and reaction time surpassed the high school mean, and subjective symptoms reported during the evaluation decreased 94% from baseline values.

After 6 months with no additional treatments or interventions of any kind, the patient was retested. His verbal memory score was maintained at 73%. His impulse control composite score continued to improve by decreasing to only 2; however, his visual memory score decreased and was only 13% better than the baseline value. His reaction time was still 36% better than the baseline value but was >0.1 second worse than his 40-treatment exit score of 0.53 second. The patient reentered treatment and, after 33 additional exposures to HBOT, his verbal memory was 95% (pretreatment: 55%), visual memory was 57% (pretreatment: 38%), reaction time was 0.64 second (pretreatment: 1.03 second), visual motor speed score was 20.1 (pretreatment: 18.6), and all previously reported symptoms resolved.

DISCUSSION

In 1992, Rockswold et al²¹ reported a study of acute traumatic brain injury. Conducted from 1983 to 1989, the study enrolled 168 patients with Glasgow Coma Scale scores of ≤9. The overall mortality rate was reduced significantly, by 50%, in the HBOT group (57% in the group with increased intracranial pressure). In 2001, Rockswold et al²² reported that HBOT improved the cerebral metabolic rate for oxygen, decreased cerebrospinal fluid lactate levels (a marker of damaged brain cells), and reduced intracranial pressure. Those authors showed the ability of

TABLE 1. Neuropsychologic Test Modules

Test Module	Ability Area
Word discrimination	Attentional processes, verbal recognition
Symbol memory	Visual working memory, visual processing speed
Sequential digit tracking	Sustained attention, reaction time
Visual span	Visual attention, immediate memory
Symbol matching	Visual processing speed, learning and memory
Color click	Focused attention, response inhibition, reaction time
Three letters	Working memory, visual motor response speed

Results from these tests are computed into overall memory, reaction time, and processing speed composite scores (normative data are available at www.impacttest.com).

Fig 1. Changes in verbal and visual memory composite scores over the course of HBOT. The high school means were 87.49% (SD: 9%) for verbal memory and 77.89% (SD: 13.16%) for visual memory.

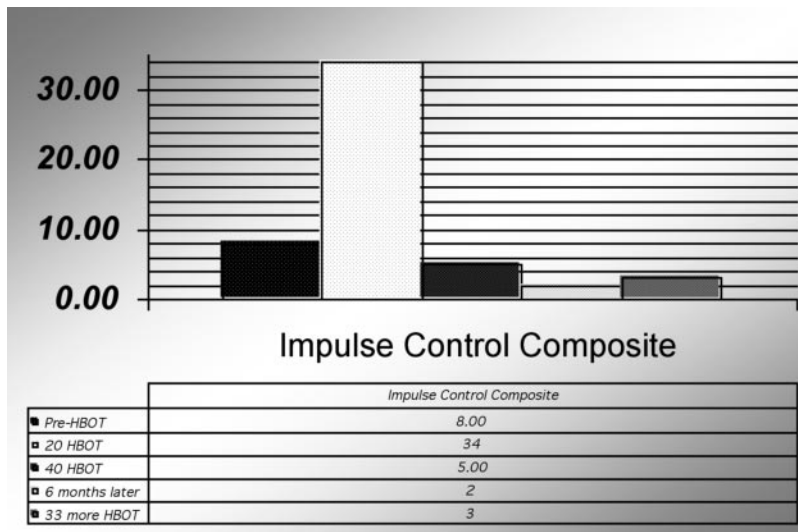
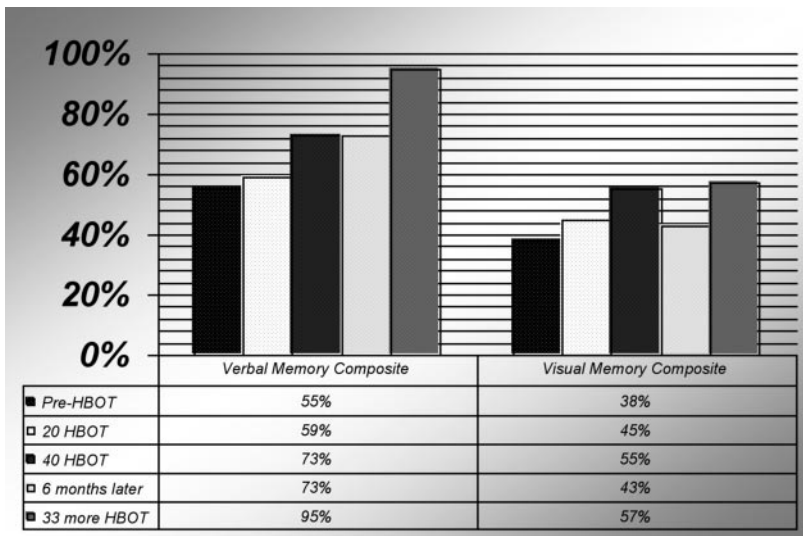
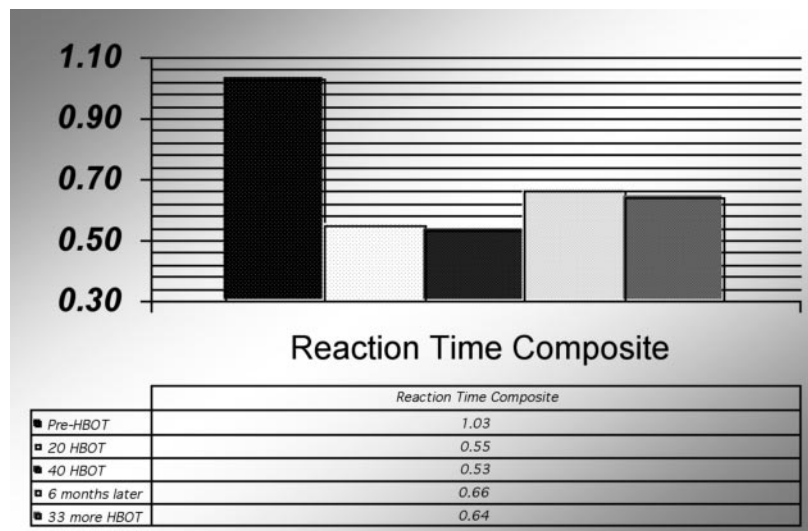


Fig 2. Impulse control composite scores. With a rapid decrease and improvement in reaction time, there is a tendency for impulsivity scores to initially increase, as shown halfway through the first treatment series, but the exit score represents a 38% improvement from the baseline value and is better than the high school mean of 9.51 (SD: 8.68).

Fig 3. Reaction time composite. Reaction time improvement bettered the high school mean of 0.565 seconds (SD: 0.08 seconds) after 40 treatments.



HBOT to recouple blood flow with metabolism. This is relevant because it is time to revise the old concept that brain injury is a condition for which there is no treatment other than supportive measures.

Furthermore, the axiom that old injuries are static or irreversible is untenable. It is now recognized in neurology that deterioration attributable to brain damage at birth may take place over 28 years.²³ This

Fig 4. Symptom scores. The computer-administered evaluation asks patients to score subjective symptoms relevant to brain injury that they may be having. The decrease in reported symptoms is consistent with the global improvement this patient displayed in the other modules of the test. The return of some symptoms after 6 months is also consistent with the partial deterioration in some of his scores, but the score decreased to 0 with additional HBOT.

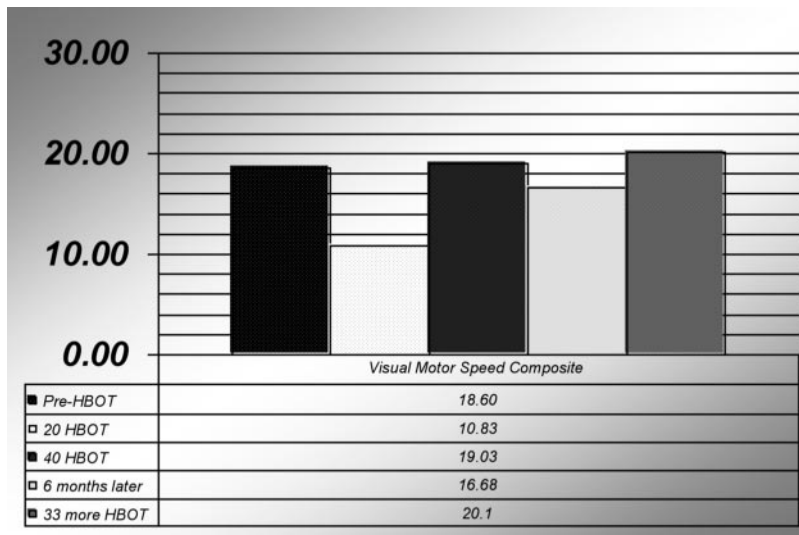
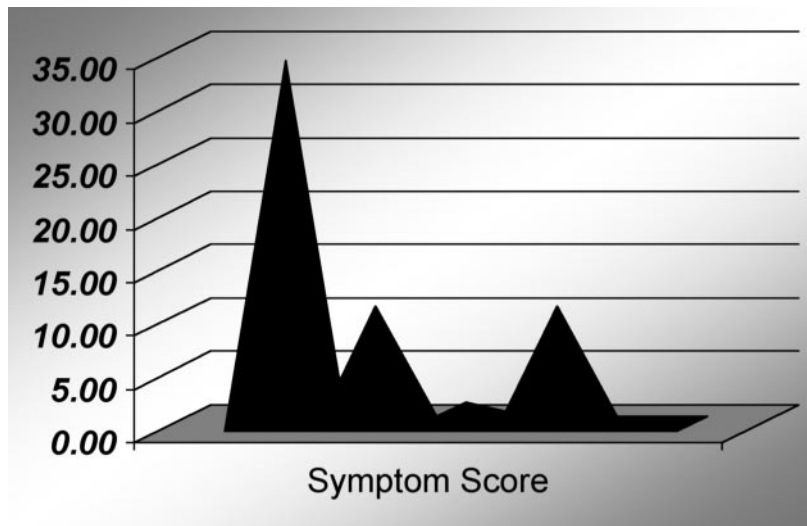


Fig 5. Visual motor speed composite score. Visual motor speed improved with treatment but remained in the borderline impaired range (high school mean: 36.81).

mirrors the adult situation.²⁴ Furthermore, stem or progenitor cells have been found in the adult brain in the past decade, and they can result in neural regeneration.²⁵ This recovery process is oxygen dependent and, on first principles, is much more likely to take place in a youngster than in an adult. There is now conclusive evidence from altitude studies that the capillary density can be increased even in the adult mammalian brain.²⁶

However, there is trepidation in using extra oxygen to treat children with neurologic problems, because of ingrained concern regarding retinopathy. Tissue hypoxia is compounded by the intravascular sequestration of leukocytes, which release oxygen free radicals. These mechanisms, which constitute the inflammatory response, seem to be activated inappropriately in reperfusion injury and are stimulated by hypoxic signaling produced by increased levels of hypoxia-inducible factor 1α ,²⁷ which also upregulates the production of vascular endothelial growth factor. Therefore, it seems to be hypoxia, created by abrupt reduction of incubator oxygen levels, and not oxygen toxicity that is responsible for neovascularization in retinopathy of prematurity.^{28,29}

The computer assessment used in this case seems to be a very useful tool for monitoring changes in neurocognitive function after a brain injury and has application beyond the evaluation of sports-related concussions. HBOT may be useful in the treatment of neurologic injury even if applied in the nonacute period,^{30,31} as it was with this patient. Patients with DCS sometimes needed to be treated 100 times before a clinical plateau was reached, and the block of 33 additional treatments continued to improve this patient's neurocognitive function when given at a later date (7 months after the end of his first block of treatments). On the basis of previous experience with DCS cases, this patient might have maintained some of his gains better if he had received additional treatments in the 6-month period after his initial treatment ended, as the continued improvement in his neurocognitive test results with resumption of therapy 7 months later indicates. No conclusion should be drawn from this case regarding how to use HBOT to treat a newborn with evidence of fetal alcohol exposure, because the pathologic features of a more acute exposure to alcohol may not be like those of an old exposure. The lack of appreciation of the pathologic differences in acute versus chronic brain inju-

TABLE 2. Scoring Generated by Computer Assessment of Neurocognitive Function

ImPACT Clinical Report	Before HBOT	After 20 HBOT Treatments	After 40 HBOT Treatments	6 mo Later	After 33 More HBOT Treatments, 73 Total
Examination language	English	English	English	English	English
Word memory					
Hits (immediate), no.	10	11	12	12	11
Correct distractors (immediate), no.	11	12	12	12	10
Learning correct, %	88	96	100	100	86
Hits (delay), no.	10	11	11	11	9
Correct distractors (delay), no.	12	12	12	11	11
Delayed memory correct, %	92	96	96	92	83
Total correct, %	90	96	98	96	85
Design memory					
Hits (immediate), no.	8	9	8	7	6
Correct distractors (immediate), no.	4	6	6	8	6
Learning correct, %	50	63	58	63	50
Hits (delay), no.	9	7	7	4	6
Correct distractors (delay), no.	7	5	8	10	9
Delayed memory correct, %	67	50	63	58	63
Total correct, %	58	56	60	60	56
X's & O's					
Total correct (memory), no.	2	4	6	3	7
Total correct (interference), no.	72	41	85	71	72
Average correct reaction time (interference), s	0.84	0.84	0.81	1.16	1.13
Total incorrect (interference), no.	8	34	5	2	2
Average incorrect reaction time (interference), s	1.57	1.28	0.58	1.75	0.43
Symbol match					
Total correct (symbols), no.	27	26	27	27	26
Average correct reaction time (symbols), s	2.06	2.46	2.36	2.46	2.36
Total correct (symbols hidden), no.	2	0	2	2	9
Average correct reaction time (symbols hidden), s	1.70	0.00	2.23	6.24	3.95
Color match					
Total correct, no.	1	0	0	0	0
Average correct reaction time, s	1.55	0.00	0.00	0.00	0.00
Total commissions, no.	0	0	0	0	1
Average commissions reaction time, s	0.00	0.00	0.00	0.00	1.41
Three letters					
Total correct, no.	2	4	5	5	5
Average correct reaction time, s	8	12	15	15	15
Total letters correct, %	53	80	100	100	100
Average time to first click, s	3.44	4.08	4.33	4.57	3.84
Average counted, no.	6.4	5.6	6.4	5.2	8
Average counted correctly, no.	6.4	3.8	5.6	5.2	7.4
Composite scores					
Memory composite (verbal), %	55	59	73	73	95
Memory composite (visual), %	38	45	55	43	57
Visual motor speed composite score	1.03	0.55	0.53	16.68	20.10
Impulse control composite score	8	34	5	2	3

ries and how to treat such injuries has produced a legacy of equivocal results. Dosage matters with HBOT, especially in treating chronic brain injuries. Pressures used for treatment of diabetic foot ulcers (2.4 ATA) or acute DCS (2.8 ATA) probably will not produce the desired healing of mature brain injuries.

In any situation in which application of appropriate measurements gives concrete evidence of changes induced by treatment, the significance of limited numbers of patients is increased. In a sense, this FAS patient acted as his own control, which was facilitated by the level of documentation that the computer-generated neurocognitive evaluation was able to provide. Low-pressure HBOT is a therapy with an extremely low risk profile and relatively low cost, with potential benefits that seem to be significant and measurable for a condition considered incurable, with no treatment at our disposal. In this case, a youth with 15-year-matured FAS benefited from a short course of low-pressure HBOT and sus-

tained durable cognitive improvements. Given the implications, these results should receive consideration for broader study as soon as possible.

REFERENCES

1. May PA, Gossage JP. Estimating the prevalence of fetal alcohol syndrome: a summary. *Alcohol Res Health.* 2001;25:159-167
2. Harch PG, Gottlieb SF, Van Meter KW, Stabb P. HMPAO SPECT brain imaging and low pressure HBOT in the diagnosis and treatment of chronic traumatic, ischemic, hypoxic and anoxic encephalopathies. *Undersea Hyperb Med.* 1994;21(suppl):30
3. Neubauer RA, Gottlieb SF, Kagan RL. Enhancing "idling" neurons. *Lancet.* 1990;335:542
4. Neubauer RA, Gottlieb SF, Miale A Jr. Identification of hypometabolic areas in the brain using brain imaging and hyperbaric oxygen. *Clin Nucl Med.* 1992;17:477-481
5. Neubauer RA. Severe natural gas poisoning successfully treated with hyperbaric oxygen: 2 years later. In: *Proceedings of the 5th International Congress on Neurotoxicity and Occupational Neurology, Prague, Yugoslavia, September 24-27, 1990.* Vienna, Austria: European Federation of Neurological Sciences; 1990:10

6. Harch PG, Gottlieb SF, Van Meter KW, Stabb P. HMPAO SPECT brain imaging of acute CO poisoning and delayed neuropsychological sequelae (DNSS). *Undersea Hyperb Med*. 1994;21(suppl):15
7. Harch PG, Gottlieb SF, Van Meter KW, Stabb P. The effect of HBOT tailing treatment on neurological residual and SPECT brain images in type II (cerebral) DCI/CAGE. *Undersea Hyperb Med*. 1994;21(suppl):22
8. Singhal AB, Dijkhuizen RM, Rosen BR, Lo EH. Normobaric hyperoxia reduces MRI diffusion abnormalities and infarct size in experimental stroke. *Neurology*. 2002;58:945–952
9. Nighoghossian N, Trouillas P, Adeleine P, Salord F. Hyperbaric oxygen in the treatment of acute ischemic stroke: a double-blind study. *Stroke*. 1995;26:1369–1372
10. Nighoghossian N, Trouillas P. Hyperbaric oxygen in the treatment of acute ischemic stroke: an unsettled issue. *J Neurol Sci*. 1997;150:27–31
11. Nakajima M, Kuwabara S, Uchino F, Hirayama K. Enhanced regeneration of terminal axons after hyperbaric oxygen therapy in a patient resembling progressive postpoliomyelitis muscular atrophy [in Japanese]. *Rinsho Shinkeigaku*. 1994;34:48–51
12. Calvert JW, Yin W, Patel M, et al. Hyperbaric oxygenation prevented brain injury induced by hypoxia-ischemia in a neonatal rat model. *Brain Res*. 2002;951:1–8
13. Collet J-P, Vanasse M, Marois P, et al. Hyperbaric oxygen for children with cerebral palsy: a randomised multicentre trial. *Lancet*. 2001;357:582–586
14. Hardy P, Collet JP, Goldberg J, et al. Neuropsychological effects of hyperbaric oxygen therapy in cerebral palsy. *Dev Med Child Neurol*. 2002;44:436–446
15. Montgomery D, Goldberg J, Amar M, et al. Effects of hyperbaric oxygen therapy on children with spastic diplegic cerebral palsy: a pilot project. *Undersea Hyperb Med*. 1999;26:235–242
16. Marois P, Vanasse M. Hyperbaric oxygen therapy and cerebral palsy. *Dev Med Child Neurol*. 2003;45:646–648
17. Stoller KP. Quantification of neurocognitive changes before and after delayed hyperbaric oxygen therapy in a case of carbon monoxide poisoning. Presented at the Undersea and Hyperbaric Medical Society Gulf Coast Chapter 2004 annual scientific meeting; Dallas, Texas, August 5–7, 2004
18. Collins MW, Lovell MR, Mckeag DB. Current issues in managing sports-related concussion. *JAMA*. 1999;282:2283–2285
19. Collins MW, Grindel SH, Lovell MR, et al. Relationship between concussion and neuropsychological performance in college football players. *JAMA*. 1999;282:964–970
20. Iverson GL, Lovell MR, Collins MW. Interpreting change on ImPACT following sport concussion. *Clin Neuropsychol*. 2003;17:460–467
21. Rockswold GL, Ford SE, Anderson DC, Bergman TA, Sherman RE. Results of a prospective randomized trial for treatment of severely brain injured patients with hyperbaric oxygen. *J Neurosurg*. 1992;76:929–934
22. Rockswold SB, Rockswold GL, Vargo JM, et al. Effects of hyperbaric oxygenation therapy on cerebral metabolism and intracranial pressure in severely brain injured patients. *J Neurosurg*. 2001;94:403–411
23. Saint Hilaire MHS, Burke RE, Bressman SB, Brin MF, Fahn S. Delayed-onset dystonia due to perinatal or early childhood asphyxia. *Neurology*. 1991;41:216–222
24. Burke RE, Fahn S, Gold AP. Delayed-onset dystonia in patients with “static” encephalopathy. *J Neurol Neurosurg Psychiatry*. 1980;43:789–797
25. Steindler DA, Pincus DW. Stem cells and neurogenesis in the adult human brain. *Lancet*. 2002;359:1047–1054
26. Harik SI, Behmand RA, LaManna JC. Hypoxia increases glucose transport at blood-brain barrier in rats. *J Appl Physiol*. 1994;77:896–901
27. Stamler JS, Jia L, Eu JP, et al. Blood flow regulation by S-nitrosohemoglobin in the physiological oxygen gradient. *Science*. 1997;276:2034–2037
28. Pugh CW, Ratcliffe PJ. Regulation of angiogenesis by hypoxia: role of the HIF system. *Nature Med*. 2003;9:677–684
29. Calvert JW, Zhou C, Zhang JH. Transient exposure of rat pups to hyperoxia at normobaric and hyperbaric pressures does not cause retinopathy of prematurity. *Exp Neurol*. 2004;189:150–161
30. Ziser A, Shupak A, Halpern P, Gozal D, Melamed Y. Delayed hyperbaric oxygen treatment for acute carbon monoxide poisoning. *Br Med J (Clin Res Ed)*. 1984;289:960
31. Ersanli D, Yildiz S, Togrol E, Ay H, Qyrdedi T. Visual loss as a late complication of carbon monoxide poisoning and its successful treatment with hyperbaric oxygen therapy. *Swiss Med Wkly*. 2004;134:650–655

Quantification of Neurocognitive Changes Before, During, and After Hyperbaric Oxygen Therapy in a Case of Fetal Alcohol Syndrome

Kenneth P. Stoller

Pediatrics 2005;116:586-591; originally published online Sep 15, 2005;

DOI: 10.1542/peds.2004-2851

This information is current as of October 1, 2005

Updated Information & Services	including high-resolution figures, can be found at: http://www.pediatrics.org/cgi/content/full/116/4/e586
References	This article cites 29 articles, 8 of which you can access for free at: http://www.pediatrics.org/cgi/content/full/116/4/e586#BIBL
Subspecialty Collections	This article, along with others on similar topics, appears in the following collection(s): Therapeutics & Toxicology http://www.pediatrics.org/cgi/collection/therapeutics_and_toxicology
Permissions & Licensing	Information about reproducing this article in parts (figures, tables) or in its entirety can be found online at: http://www.pediatrics.org/misc/Permissions.shtml
Reprints	Information about ordering reprints can be found online: http://www.pediatrics.org/misc/reprints.shtml

American Academy of Pediatrics

DEDICATED TO THE HEALTH OF ALL CHILDREN™

